

Morphological analysis of four pre-Iron Age hunter-gatherer skeletons from southern Africa housed at the KwaZulu-Natal Museum

M Steyn, D Botha. Forensic Anthropology Research Centre, Department of Anatomy, University of Pretoria, South Africa

August 2014

Introduction

The remains of four individuals were submitted for analysis. As no information on the background, burial styles etc. is available, this report follows an approach similar to what would be the case for forensic case analysis.

All remains submitted were of adult individuals, as could be deduced from the fact that all long bone epiphyses were obliterated and the permanent teeth had erupted as far as could be ascertained. For purposes of age estimation, standard methods of analysis were used (İşcan & Steyn 2013). This included assessment of cranial suture closure (Acsadi & Nemeskeri 1970), pubic symphysis (Brooks & Suchey 1990) and general degenerative changes, including changes in the first rib (Kunos et al. 1999). In addition, the degree of attrition of the teeth was observed (Molnar 1971, Scott 1979).

Sex was assessed using the morphological features of the pelvis (Phenice 1969, Ferembach 1980, İşcan & Steyn 2013) and skull (Krogman 1939, Buikstra & Ubelaker 1994, İşcan & Steyn 2013) where possible. In addition, measurements of the long bones were used to supplement the assessment of sex where possible. For this purpose, data from South African blacks were used (Steyn & İşcan 1999, Asala et al. 2004) as it is probably the most relevant data available.

Similarly, regression formulae of South African blacks were used to calculate antemortem stature (Lundy & Feldesman 1987) as they are most probably the most relevant in this regard. All skeletons were also assessed for signs of trauma and pathology.

In order to gain more information on the population affinity and origin of these individuals, a FORDISC 3 analysis was performed where crania were available (Ousley & Jantz 2012). FORDISC 3 is an example of an analytic programme that uses discriminant function analysis, in order to assess sex and/or ancestry from unknown skeletal remains. When cranial or post-cranial measurements are entered, discriminant function formulae are created using existing data in the data base from various populations. For this purpose, a selection of possible populations of origin must be made. Statistical output includes group membership (sex or ancestry), cross-validated classification accuracy, posterior probabilities and typicalities. It is not good practice to use this software if the population that one is examining is not represented in the database, which of course in this case is not possible since this is an archaeological case. Therefore in this case the following populations were selected: Teita,

Bushmen (Khoesan) and Zulu. The Khoesan sample in FORDISC 3 is derived from the original Howell's data (1973).

1. Human skeletal remains: Eland Cave, 25/37, 2530 F Ex-ethno

Inventory

The remains consisted of a complete left first rib, one right rib that had been fractured postmortem, left first metatarsal and the distal half of the left tibia (Fig. 1.1). These elements are shown in more detail in Figures 1.2 to 1.5. All measurements that could be taken from this skeleton are shown in Table 1.

Sex

Sex could not be determined due to the absence of the cranium, pelvis and long bones.

Age

The distal epiphysis of the tibia was completely closed, suggesting that the individual was older than 17 (if male) or 20 (if female) years. Also, no osteophytes were present on the distal articular surface of the tibia. Analysis of the costal face of the first rib, however, showed that the surface was irregular and the margins were rugged with swollen projections, which were consistent with an age estimate of 50+ years. It is thus possible that the remains belonged to a mature or older adult.

Ancestry

Ancestry could not be established, as no cranial remains were present.

Stature

Stature could not be calculated due to an incomplete tibia and absence of other long bones.

Dentition

No teeth were present.

Trauma and pathology

No trauma or pathology was observed.

Factors of individualization

No individualizing markers were present.

Conclusion

The remains were probably that of a mature adult individual. Sex, ancestry and stature could not be estimated as the remains were too incomplete.

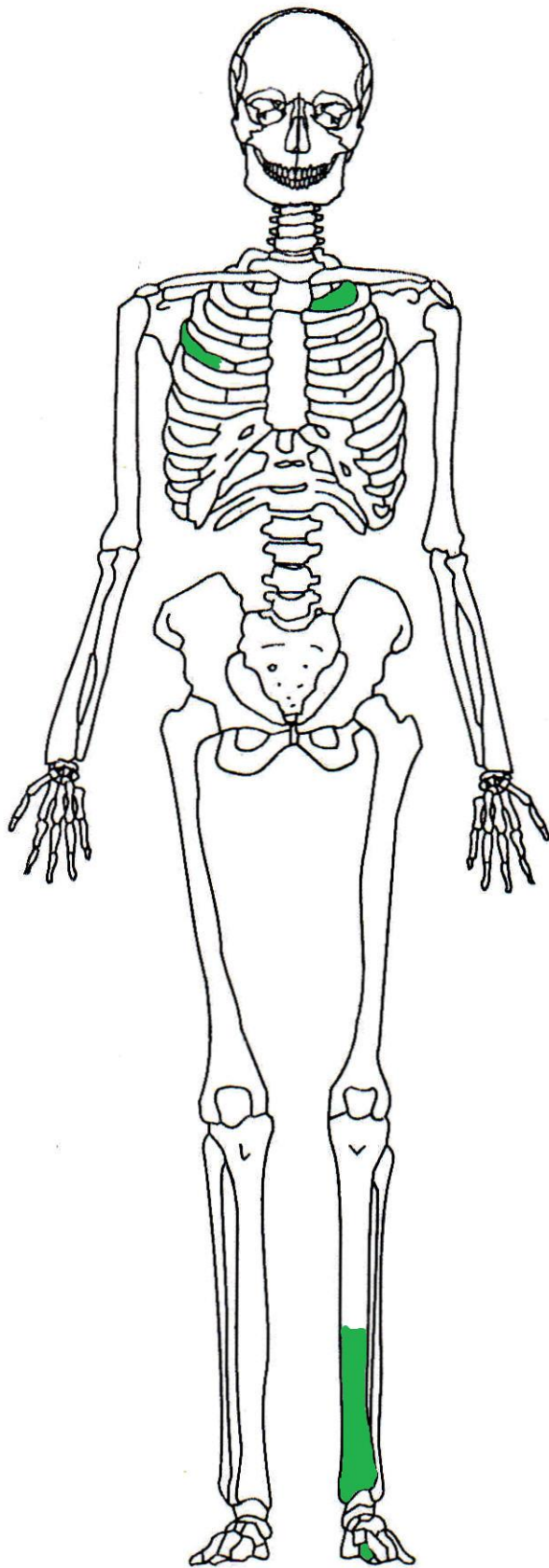


Fig.1.1. Skeletal elements present in the Eland Cave individual (anterior view).



Fig. 1.2. Left first rib (cranial view).



Fig. 1.3. Right rib (fractured).

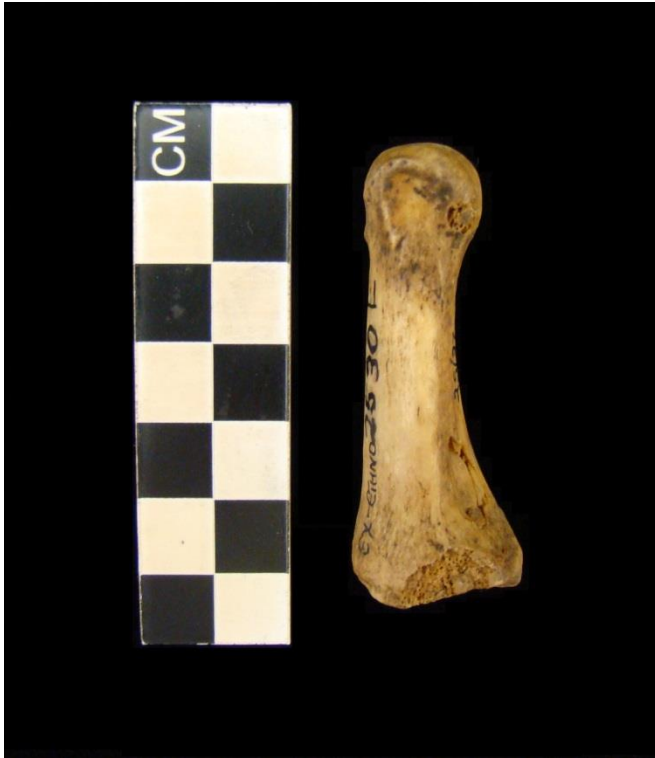

Fig.1.4. Left first metatarsal.



Fig.1.5. Left distal tibia.

2. Human skeletal remains: Champagne Castle, 2009/023

Inventory

The remains were comprised of a complete cranium and mandible, right humerus, right ulna, right radius, left pubic symphysis, right os coxa (damaged postmortem), one cervical vertebra and a few small fractured bone pieces (Fig. 2.1). These are shown in more detail in Figs. 2.2 to 2.6. The cranium had been painted with varnish. The cranial and postcranial measurements that were possible are shown in Table 1.

Sex

The presence of a preauricular sulcus and very wide greater sciatic notch indicated a female. The presence of this pre-auricular sulcus indicates that this individual had most probably borne at least one child during her lifetime. Unfortunately the pubis and ischium were damaged postmortem and could therefore not be used for morphological sex determination. Small mastoids, nuchal crest and glabella, as well as sharp supraorbital margins were also characteristic of a female individual. The humeral epicondylar breadth of 57 mm and femoral head diameter of 42 mm also classified this individual as female.

Age

Cranial suture closure indicated that this individual was aged 15 to 40 years. The pubic symphysis displayed phase 4 (23 to 57 years) with a mean of 35.2 years. Also, the sphenoccipitalis synchondrosis was fused, suggesting that the individual was older than 25 years. These estimates suggest that the individual were most likely a young adult. An age range of 20 to 39 years were assigned following standardization guidelines described by Falys and Lewis (2011).

Ancestry

A wide interorbital breadth, prognathic facial profile and smooth zygomaxillary suture indicated an individual of African descent. Morphological analysis of the cranium showed the presence of an interparietal groove/depression to the posterior part of the parietal bones on either side of the sagittal suture, as well as an inferior frontal eminence (only on the right side) and bilateral mons temporosphenoidalis. These features have been described as characteristic of Khoesan crania (Galloway 1937, Dart 1924, De Villiers 1968). Furthermore, the calvarium was small and had a doliocranial form (index = 77.2) with an ellipsoid shape. Crania of Negro descent often display an ovoid, rather than an ellipsoid shape as observed in this case. An ellipsoid (pentagonoid) form has been labelled to be characteristic of 'Bushmen' (De Villiers 1968). The occipital condyles were small (length: 19 mm, width: 15 mm) and did not encroach on the round-shaped foramen magnum, which is a feature often observed in Khoesan crania (Galloway 1937, De Villiers 1968).

Using FORDISC 3, the individual was compared to other African groups which included Zulu, Teita and Bushmen (Howell's data, 1973). Multigroup analysis classified the individual as Teita (female) with an accuracy of 68.0%, and secondly as 'Bushman' (female) with a 61.2% accuracy.

Stature

The maximum length of the humerus indicated an antemortem stature of 153.8 ± 3.72 cm. This estimate is on average shorter than that of South African black females, but similar to figures reported for Khoesan/Bushmen groups (Tobias 1961, 1962, Truswell & Hansen 1976).

Dentition

Eight permanent teeth and one tooth root was present: maxillary right canine (Fig. 2.7), right central incisor, left lateral incisor (Fig. 2.8) and root of the second premolar, as well as the mandibular right second and third molars, left canine (Fig. 2.9) and left second and third molars. Dental measurements are given in Table 2. Moderate to advanced wear was present on all teeth. Periodontal disease was observed around the mandibular first molars and second premolars, as well as the maxillary molars and premolars. Caries was present on all four lower molars (second and third molars) on the buccal sides (Fig. 2. 10), as well as the upper right canine (distal side) and remaining root of the upper left second premolar (occlusal surface). An abscess was evident on the maxilla in the area of the second premolar root (Fig.2.11). The mandibular first molars, as well as the maxillary first, second and third molars and second premolars were lost antemortem.

Trauma and pathology

The right parietal bone presented with a depressed fracture that appeared to be unhealed and possibly occurred perimortem (Fig. 2.12). The lesion measures 40 mm by 17 mm, and was situated 25 mm behind the coronal suture and 24 mm to the right of the sagittal suture. It was oblong in shape. The outer surface of fracture suggests that the bone was wet/elastic at the time the defect occurred. The bone showed postmortem dehydration before varnish was applied, trapping dirt on the fracture which made observation of the compression-tension patterns difficult. Figure 2.13 shows a CT scan image of the lesion in which it can be seen that the fracture penetrates the outer table of the cranium. The inner table, however, remained intact. No other signs of pathology were observed.

Factors of individualization

No individualizing factors were present.

Conclusion

The remains were most likely that of a young adult female (age estimated to be 20 to 30 years) with an estimated stature of about 154 cm. She has a fracture of her right parietal bone which most probably occurred around the time of death, as is evidenced by the green bone response. This fracture most probably reflects an episode of interpersonal violence, but it cannot be determined if this traumatic injury was the actual cause of death in this case.

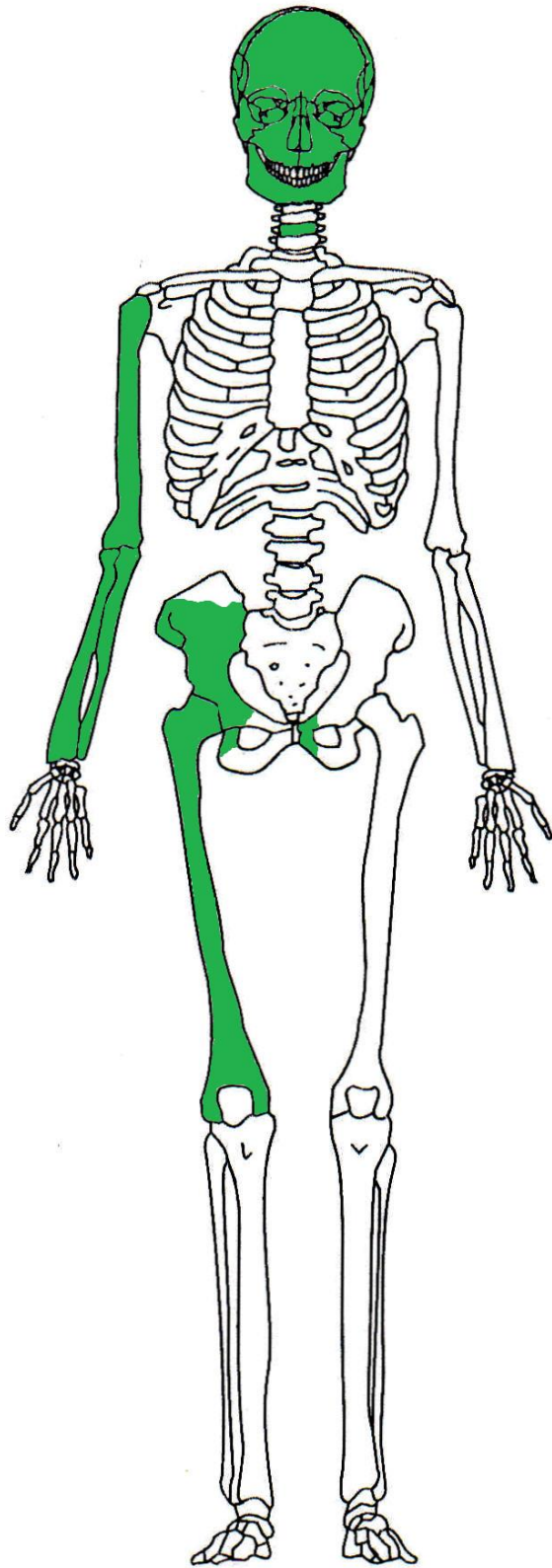


Fig.2.1. Skeletal elements present in the Champagne Castle individual (anterior view).

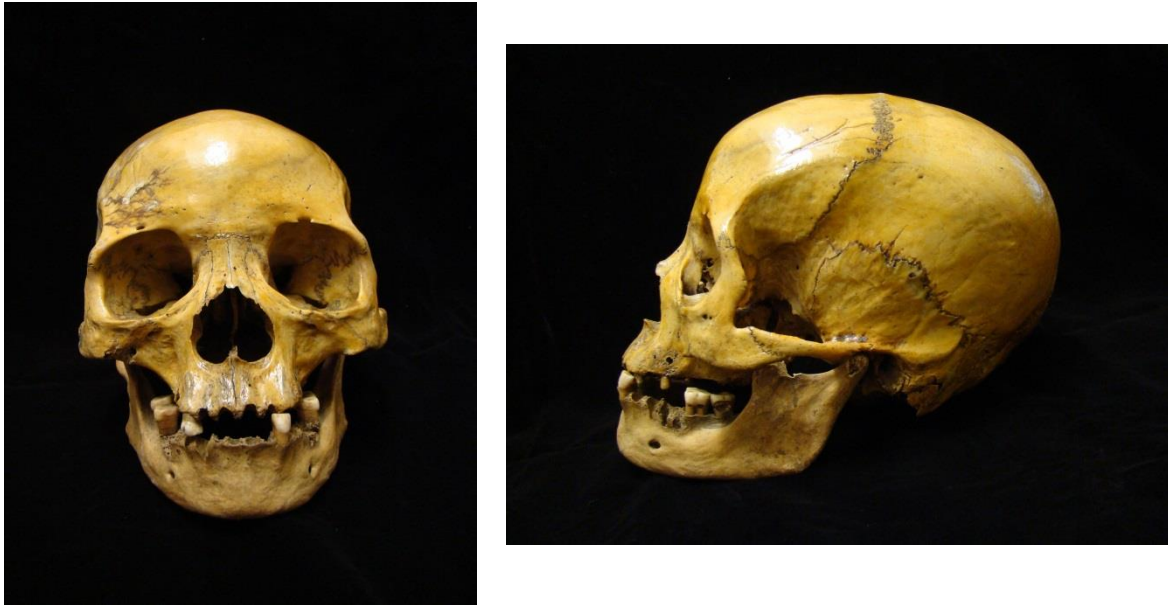

Fig.2.2. Cranium and mandible, anterior and lateral views.




Fig.2.3. Inscription on the occipital bone of the cranium.



Fig.2.4. Right upper limb (humerus, ulna and radius).



Fig.2.5. Right os coxa (damaged postmortem).

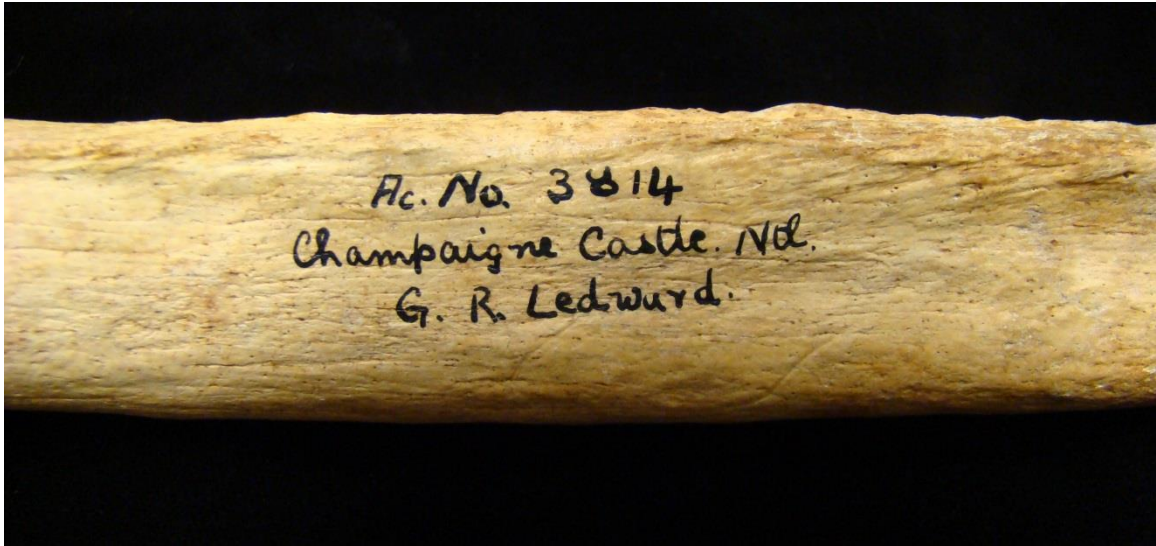


Fig.2.6. Inscription on the midshaft of the femur.

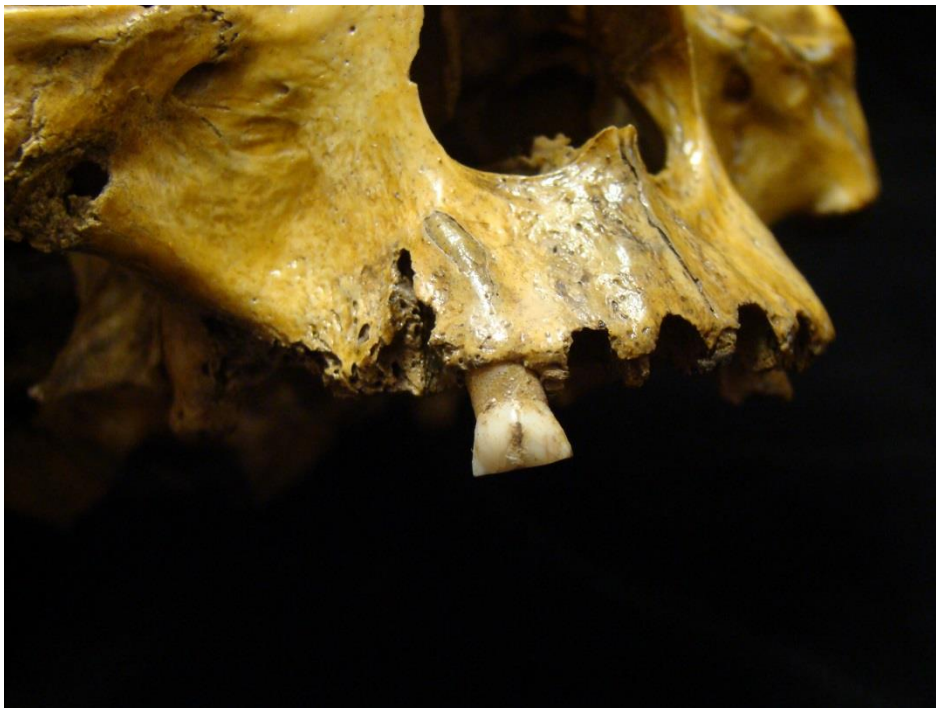

Fig.2.7. Maxillary right canine.




Fig.2.8. Maxillary right central incisor and left lateral incisor.

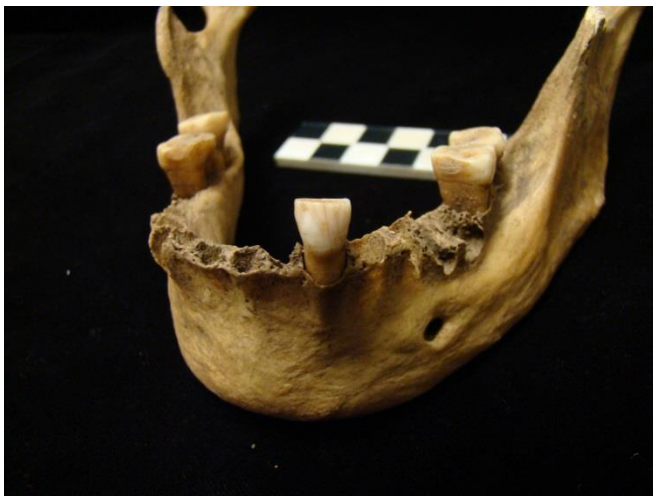

Fig.2.9. Mandibule, showing in situ teeth.

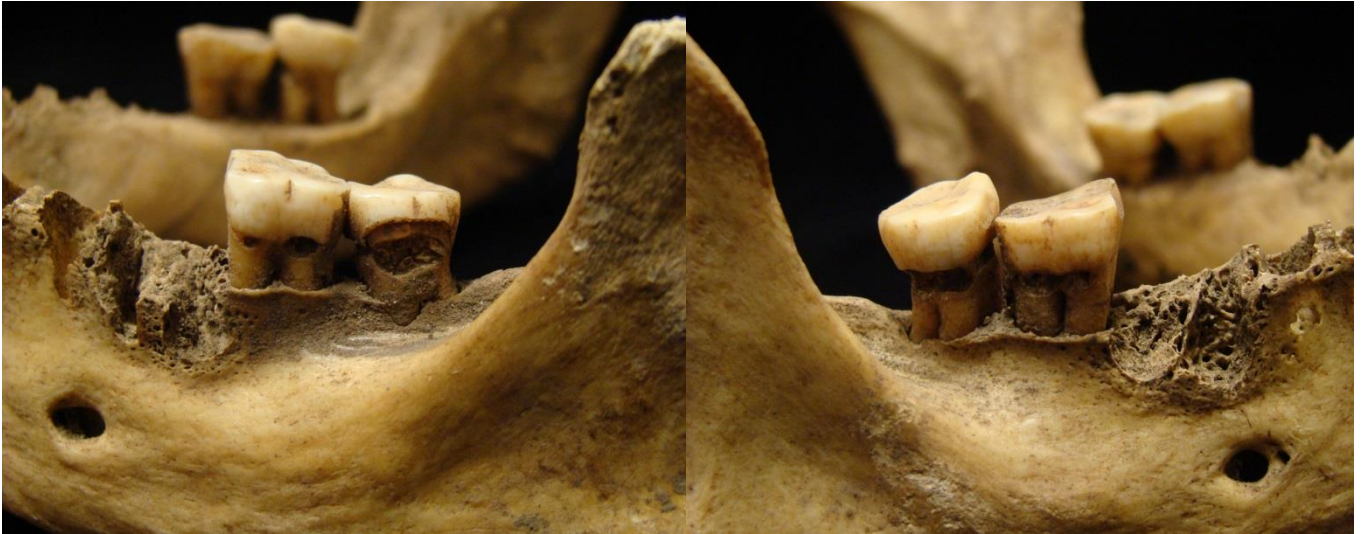

Fig.2.10. Caries of the mandibular second and third molars on the left and right sides.

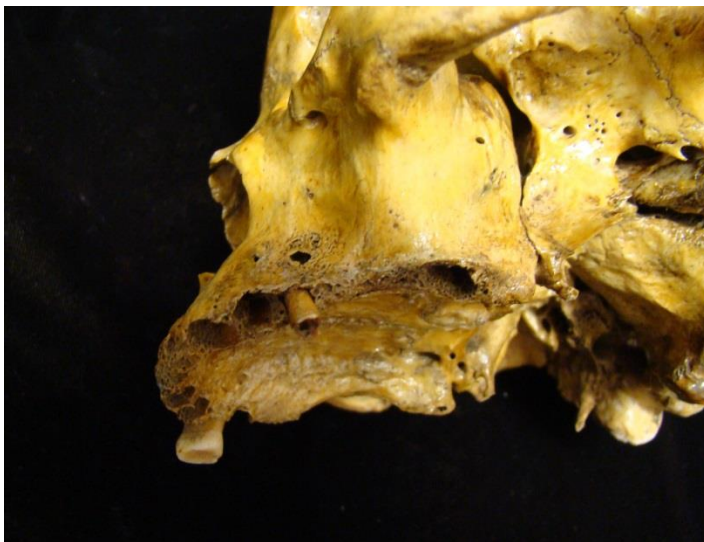


Fig.2.11. Abscess of the maxillary left second premolar.



Fig. 2.12. Depressed fracture on the right parietal bone.

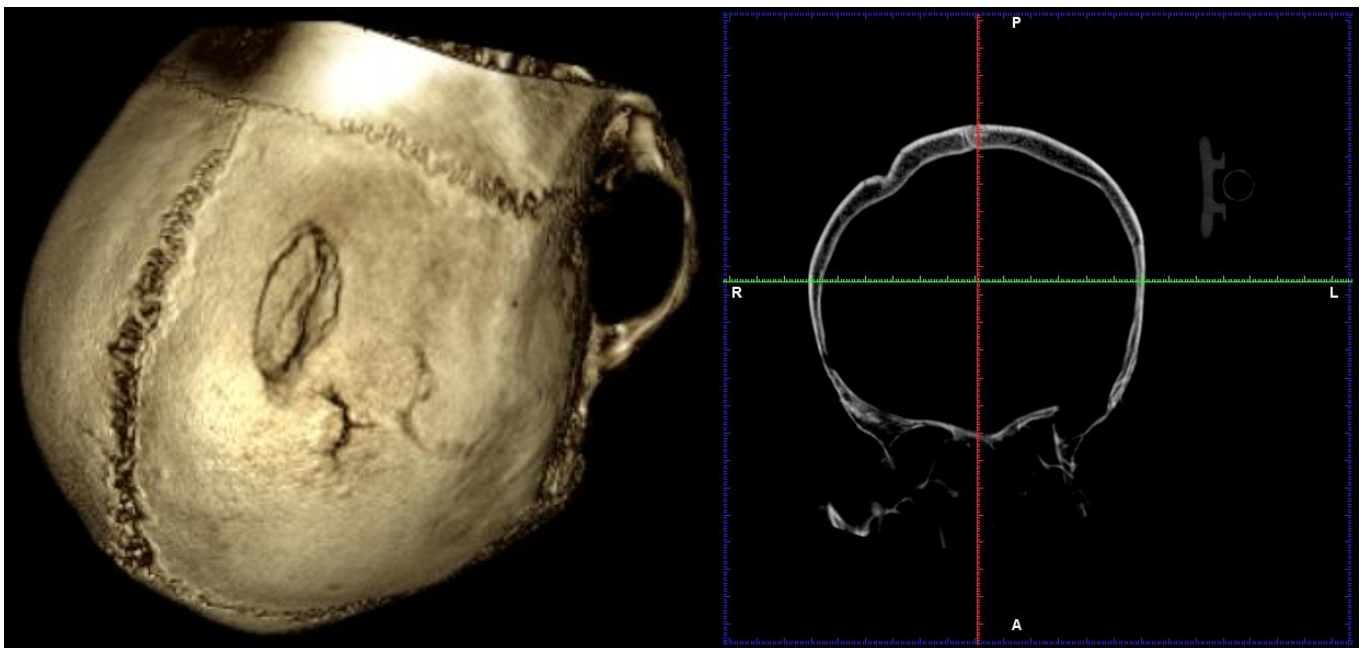


Fig.2.13. CT scan of depressed fracture. Note that the x-ray image (right side) shows that the lesion penetrates the outer table of the cranium, but leaves the inner table intact.

3. Human skeletal remains: Mfongosi Bushman remains, 25/36.

Inventory

The mandible, frontal bone, left and right parietal bones and occipital bone of the cranium were present, but were disarticulated. The left humerus, left femur and left tibia were also present, but the proximal and distal epiphyses were damaged postmortem (Fig. 3.1). These elements are shown in more detail in Figures 3.2 to 3.4. The measurements that were taken are shown in Table 1.

Sex

The mandible was small and gracile with a pointed chin. The glabella was smooth and the supraorbital margins sharp. These characteristics indicated a female individual. The long bones present could not be used for metric sex determination as the proximal and distal epiphyses were damaged postmortem.

Age

Some closure of the cranial sutures was evident, although they were not completely obliterated. As the cranial elements were separated, however, they were difficult to judge. No age estimation could be made, but the long bones appeared to be adult size and all teeth present were permanent and showed moderate to advanced dental wear. The advanced tooth loss and mandibular atrophy suggest that this was not a young adult individual.

Ancestry

Ancestry could not be determined due to the fragmentary nature of the cranial elements.

Stature

Stature could not be estimated due to the lack of complete long bones.

Dentition

Five teeth were present. Due to extensive wear on all teeth it was difficult to side. It was, however, possible to distinguish between the tooth types. There were one lower molar, one lower first incisor, two upper incisors (possibly first and second), as well as one upper premolar. Caries was present on the neck of the root of the lower molar. Abscesses were observed. Figures 3.5 and 3.6 show the molar and premolar/incisors, respectively. No dental measurements were taken due to the presence of advanced attrition.

Trauma and pathology

No trauma or pathology was observed.

Factors of individualization

No factors of individualization were present, although two museum tags accompanying the remains stated that the bones belonged to a Bushman (Fig. 3.7).

Conclusion

The remains most probably belonged to an older, adult female individual. All teeth were severely worn.

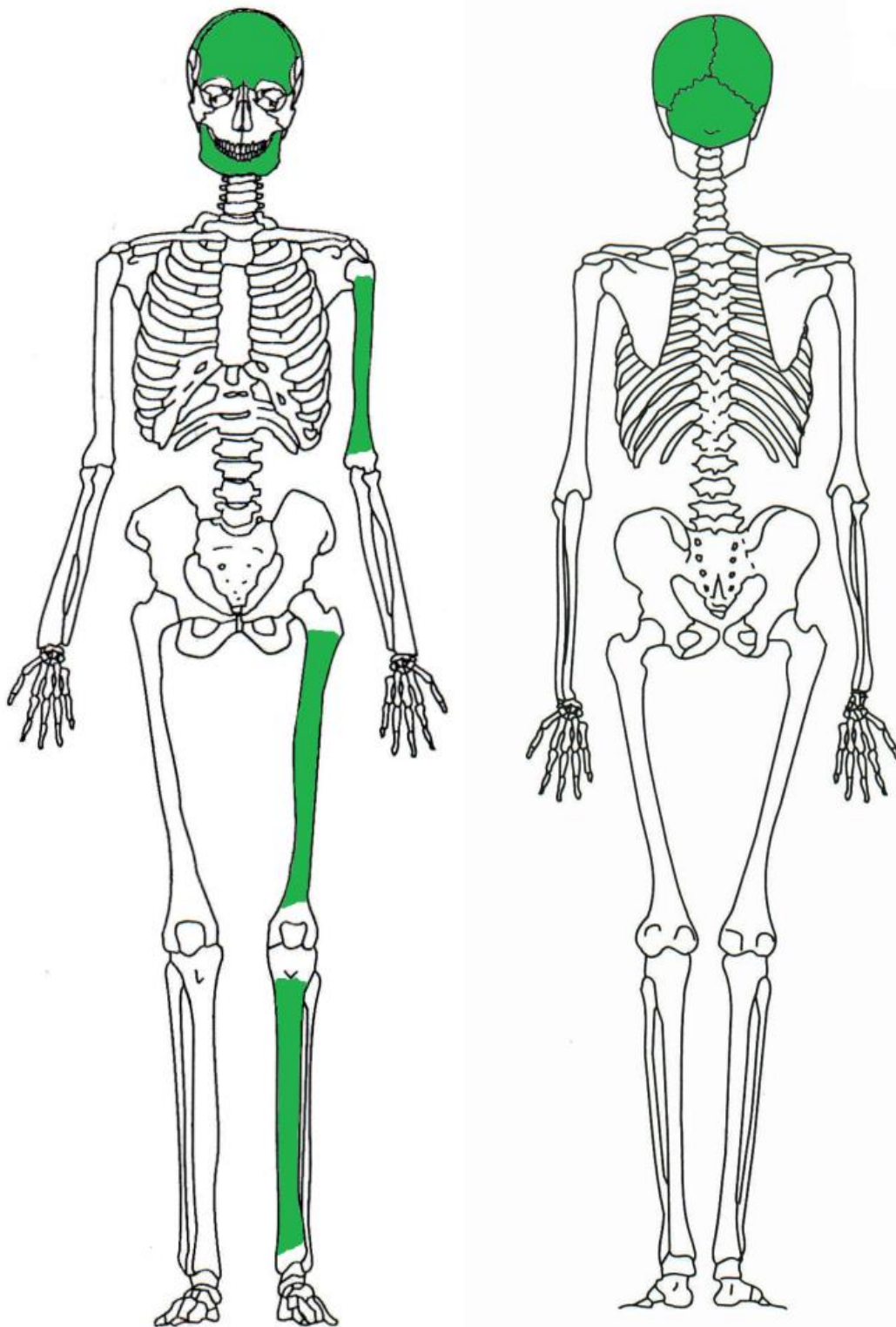


Fig.3.1. Skeletal elements present in the individual from Mfongosi (anterior and posterior views).



Fig.3.2. Frontal bone, parietal bones and occipital bone.



Fig.3.3. The mandible.



Fig.3.4. Left humerus, left femur and left tibia (epiphyses damaged postmortem).

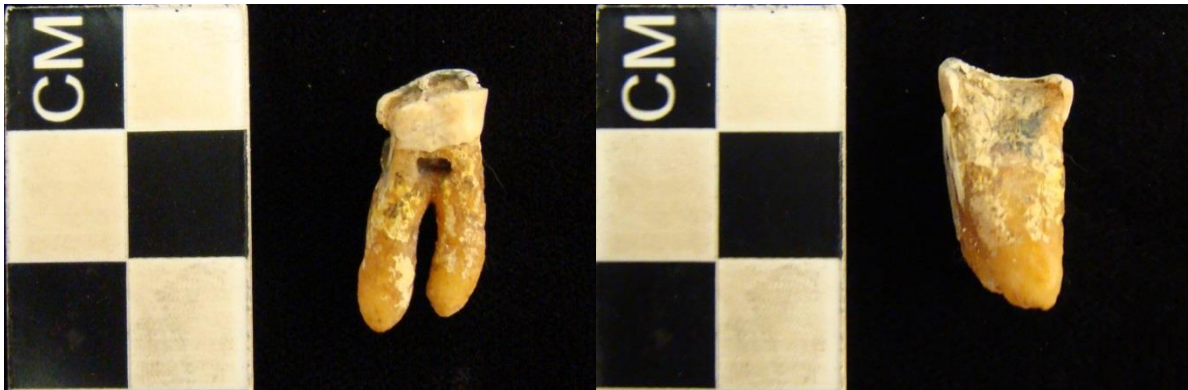

Fig.3.5. Mandibular molar (mesodistal and buccolingual views). Note caries on the neck of the root and extensive attrition.



Fig.3.6. (a) upper premolar, (b) and (c) upper incisors, (d) lower incisor. Note that the lower incisor was glued to a flat surface at one stage.

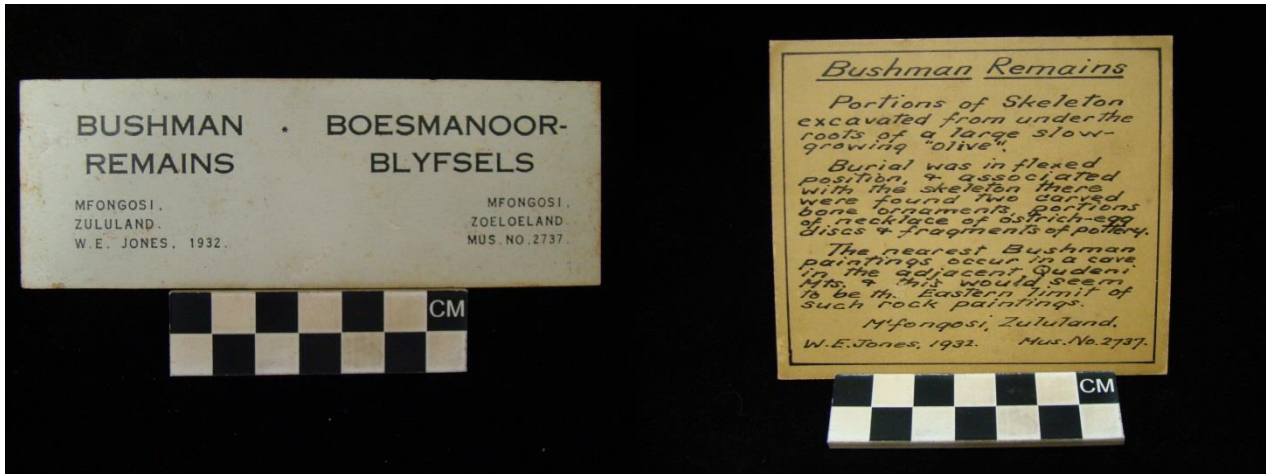


Fig.3.7. Museum tags accompanying the remains from Mfongosi.

4. Human skeletal remains: Newcastle 2378, 2007/6

Inventory

The remains consisted of a fragmented right parietal bone, left temporal bone, left inferior-lateral orbital rim fragment, right superior-lateral orbital rim fragment, both clavicles, both scapulae, left and right os coxae, both patellae, right fibula, four cervical vertebrae, four thoracic vertebrae, five lumbar, manubrium, six right ribs, seven left ribs, one rib fragment, 10 foot bones along with 10 metatarsals and 10 foot phalanges, nine metacarpals and eight hand phalanges, as well as three hand bones (Fig. 4.1). These are shown in more detail in Figures 4.2 to 4.5, and the measurements that were possible are shown in Table 1. The remains were also accompanied by a small bag of animal bones.

Sex

Small mastoid processes and sharp supraorbital margins on the cranium, as well as a wide greater sciatic notch (Fig. 4.5), preauricular sulcus and a well-defined ventral arc suggested a female individual. The presence of a well-developed preauricular sulcus suggests that this woman has had at least one child. The scapular height (119 mm) and scapular breadth (91 mm) also indicated a female (Jordanidis 1961).

Age

All long bone epiphyses that were visible were closed, and all teeth were permanent indicating an adult individual. The pubic symphysis morphology was consistent with phase 5 (27 to 66 years) with a mean age of 45.6 years. Advanced dental wear also suggest that the individual were of mature age. The individual was most likely aged between 40 and 59 years (standardized age according to Falys and Lewis, 2011).

Ancestry

Ancestry could not be determined due to the fragmentary nature of the cranial elements.

Stature

An antemortem stature of 132.1 ± 3.17 cm was calculated using the fibula. This is a short stature according to Tobias (1961, 1962), very tentatively suggesting a Khoesan affinity.

Dentition

The upper left lateral incisor, upper right first molar and lower right third molar were present. Dental measurements are given in Table 2. The molars showed advanced dental wear (Figs. 4.6 and 4.7). The incisor displayed a very small degree of wear (Fig. 4.8). The upper right first molar had caries on both the medial (caries appeared to penetrate the pulpal space) and distal (no penetration of pulpal space) sides of the crown. The lower third molar had caries on the buccal side, but the lesion did not appear to penetrate the pulpal space.

Trauma and pathology

Vertebral osteophytes were noticed on the lumbar, thoracic and cervical vertebrae, with the lumbar most severely affected (Fig. 4.9). No other pathology or trauma was present.

Factors of individualization

No individualizing factors were noticed.

Conclusion

The remains belonged to a middle aged female (probably around 40 to 59 years) with an antemortem stature of about 132 cm. Although ancestry could not be determined, the very short stature suggests Khoesan affinity.

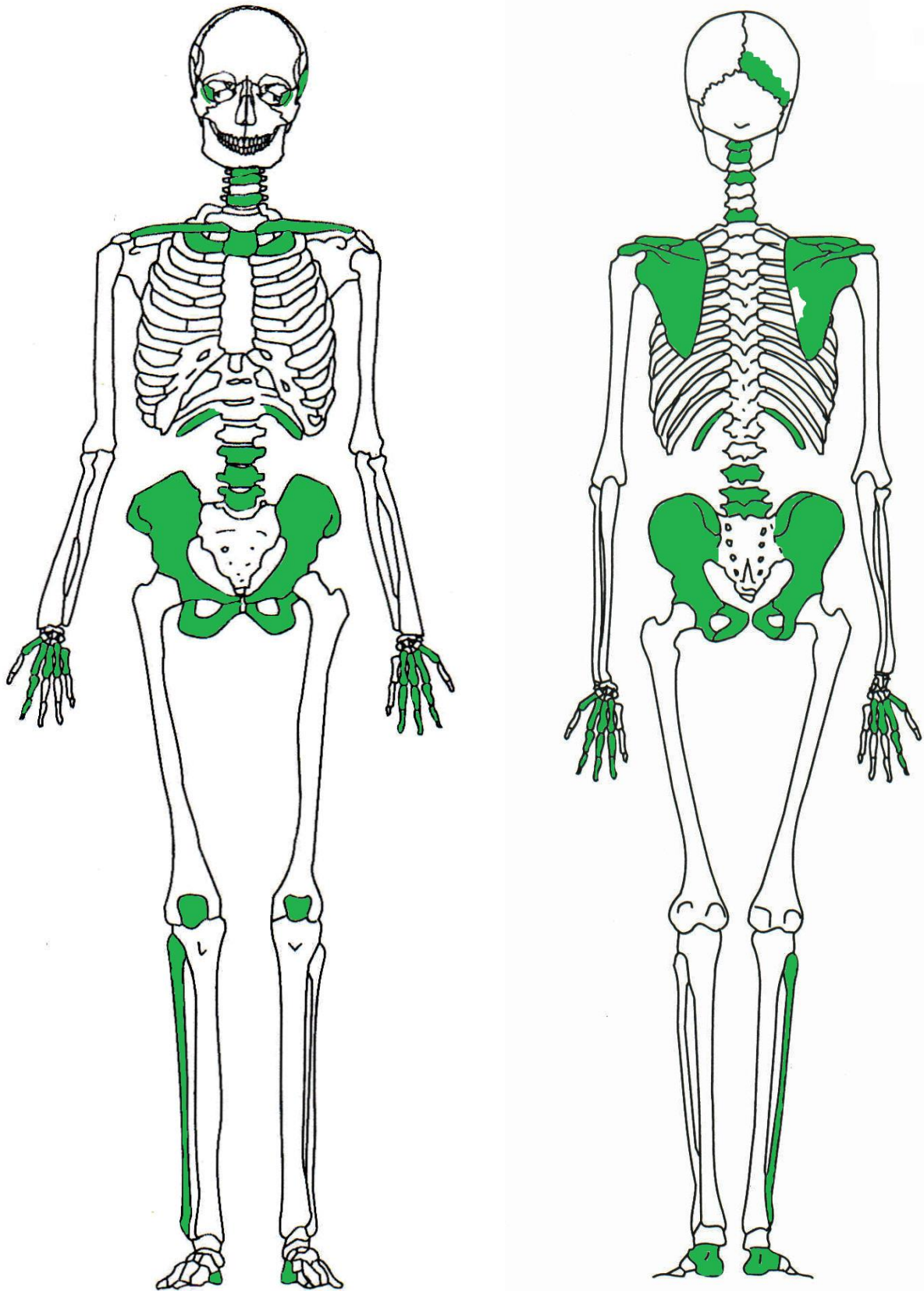


Fig.4.1. Skeletal elements present in the individual from Newcastle (anterior and posterior views).

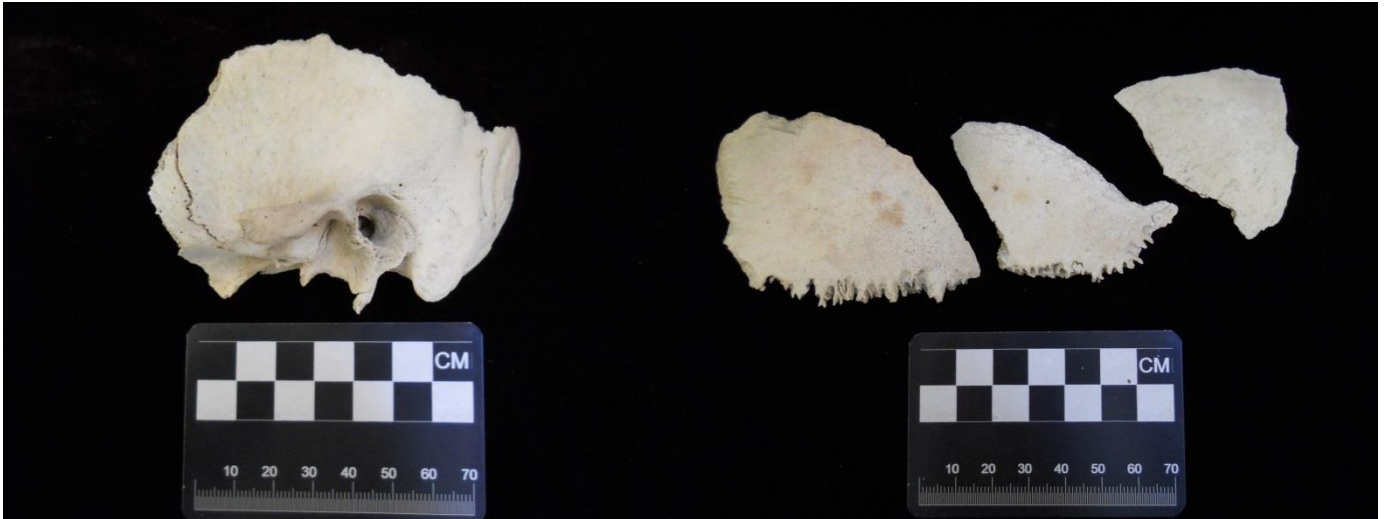


Fig.4.2. Temporal bone and fragments of the posterior part of the right parietal bone.

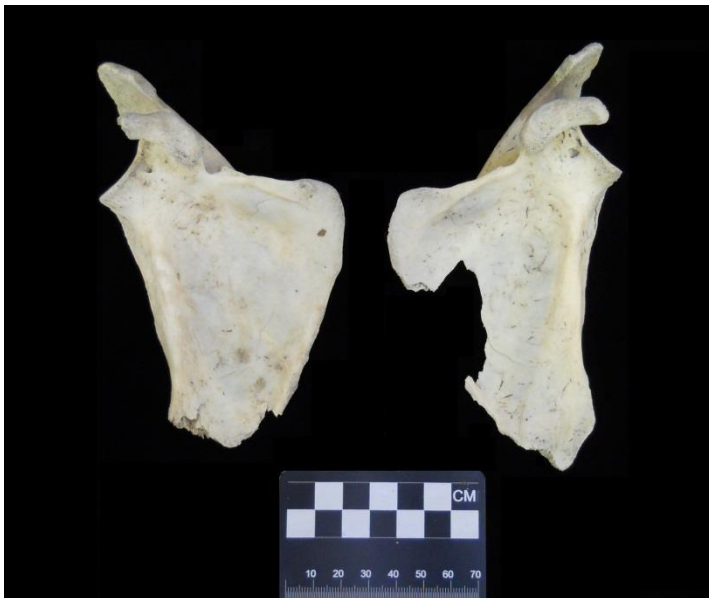

Fig.4.3. Scapulae (costal view).

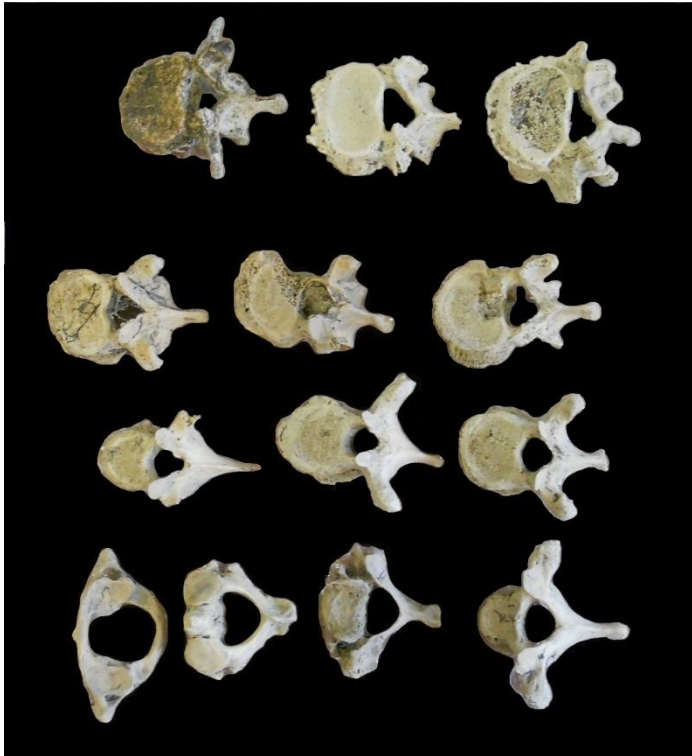


Fig.4.4. Vertebrae (dorsal view).

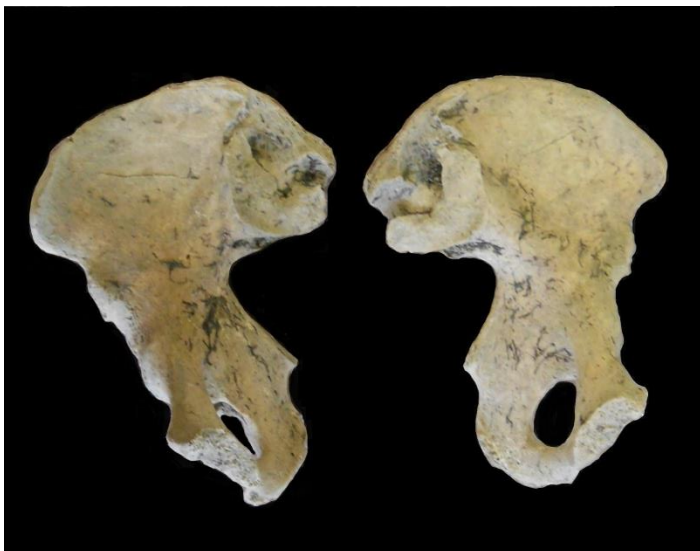

Fig.4.5. Os coxae.



Fig.4.6. Mandibular right third molar, medial and distal views.

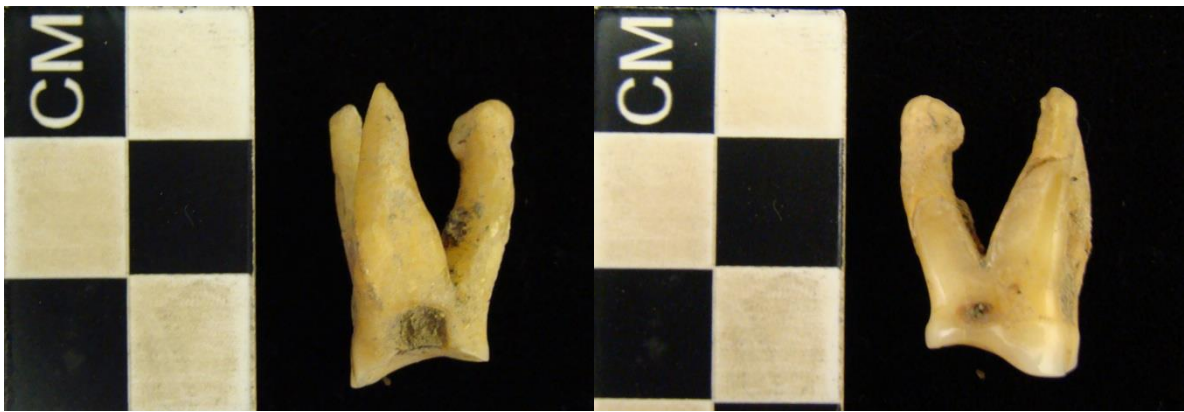

Fig.4.7. Maxillary right first molar, medial and distal views.



Fig.4.8. Maxillary left lateral incisor.

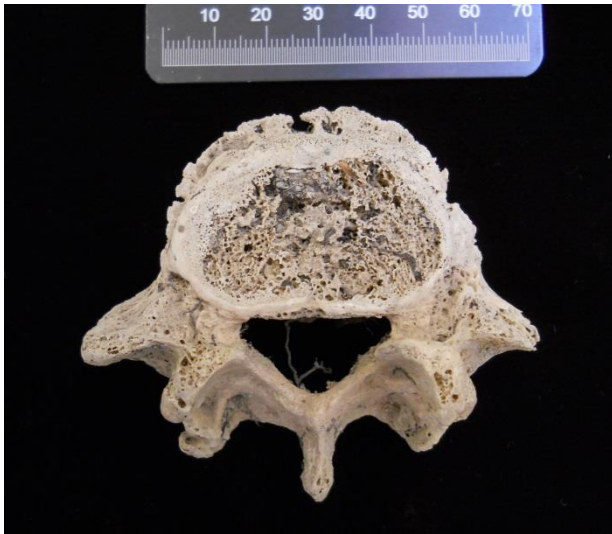

Fig.4.9. Vertebral osteophytes on the fifth lumbar vertebra (dorsal view).

Conclusion

The skeletal remains of four individuals were studied for the purpose of documentation. All skeletons are of an archaeological nature, and were therefore often incomplete or poorly preserved, which complicated analysis. Sex could only be determined in three of the four individuals, and all three were assessed to have been female. All four were adults.

The stature estimates of the Champagne Castle and Newcastle individuals were shorter than expected for black African groups and were consistent with San/Khoesan stature estimates reported in literature (Tobias 1961, 1962, Pfeiffer & Sealy 2006, Pfeiffer 2012).

Only one individual was complete enough to attempt assessment of population affinity. Determination of ancestry indicated via FORDISC that the Champagne Castle individual was likely of Khoesan origin, although it also showed a close affinity to specimens from Taita. Unfortunately the FORDISC database contains a limited number of comparative samples, and it may be worthwhile to do comparisons with other more sophisticated databases. Crania of the other three individuals were absent or not complete and could therefore not provide specific information related to their population affinity.

In general, the teeth showed considerable wear. The posterior teeth seemed to be more worn than the anterior teeth which would suggest that the teeth were used mostly for normal masticatory functions. Many of the teeth showed caries or abscessing which is somewhat surprising, as it is generally thought that hunter-gatherers show less dental decay than agriculturalists.

Trauma was only observed in one individual (Champagne Castle). The depressed fracture to the right side of the cranium most probably resulted from perimortem blunt force trauma.

This may in some cases reflect interpersonal violence, but may also be the result of an accident or fall. It is not clear whether it was the cause of death of this individual.

No signs of specific or non-specific disease were encountered. It is thus difficult to comment on the health of these individuals. Dental health suggests that caries, antemortem tooth loss and periodontal disease were common, which is consistent with a diet that includes carbohydrates (Morris 1992, Larsen 2000).

Obviously there exists the need to perform further studies on the materials at hand. Genetic analysis will no doubt make a valuable contribution to the study of these remains, and there are currently no obvious reasons why the remains cannot be sampled for further analyses.

References

- Acsádi, G. & Nemeskéri, J. 1970. *History of Human Life Span and Mortality*. Budapest: Akadémia Kiadó.
- Asala, S.A., Bidmos, M.A. & Dayal, M.R. 2004. Discriminant function sexing of fragmentary femur of South African blacks. *Forensic Sci Int*, 145 (1):25-29.
- Brooks, S.T. & Suchey, J.M. 1990. Skeletal age determination based on the os pubis: A comparison of the Acsádi-Nemeskéri and Suchey-Brooks Methods. *Human Evol*, 5:227-238.
- Buikstra JE, Ubelaker DH. 1994. *Standards for data collection from human skeletal remains*. Arkansas: Arkansas Archaeological Survey.
- Dart, R.A. 1924. The Rooiberg cranium. *S Afr J Sci*, 21:556-568.
- De Villiers, H. 1968. *The Skull of the South African Negro: A Biometrical and Morphological Study*. Johannesburg: Witwatersrand University Press.
- Ferembach, D., Schwidetzky, I. & Stloukal, M. 1980. Recommendations for age and sex diagnoses of skeletons. *J Human Evol*, 9:517-549.
- Galloway, A. 1937. Skeletal remains from Mapungubwe. In: *Mapungubwe: An Ancient Civilization on the Limpopo*. Ed.: L. Fouche. Cambridge University Press.
- Howells, W.W. 1973. Cranial variation in man. *Papers of the Peabody Museum of Archaeology and Ethnology* 67:1-259.
- Iordanidis, P. 1961. Determination du sexe par les os du squelette (atlas, axis, clavicule, omoplate, sternum). *Annales de Mdecine Legale*, 41:280-291.
- Işcan, M.Y. & Steyn, M. 2013. *The Human Skeleton in Forensic Medicine*. 3rd ed. Springfield: Charles C Thomas.
- Krogman, W.M. 1939. A guide to the identification of human skeletal material. *FBI Law Enforcement Bull* 8(8):1-29.
- Kunos, C.A., Simpson, S.W., Russell, K.F. & Hershkovitz, I. 1999. First rib metamorphosis: its possible utility for human age-at-death estimation. *Am J Phys Anthropol*, 110:303-323.
- Larsen, C.S. 2000. *Skeletons in Our Closet: Revealing Our Past through Bioarchaeology*. Princeton and Oxford: Princeton University Press.

- Lundy, J.K. & Feldesman, M.R. 1987. Revised equations for estimating living stature from long Bones of the South African Negro. *S Afr J Sci*, 83:54-55.
- Molnar, S. 1971. Human tooth wear, tooth function and cultural variability. *Am J Phys Anthropol*, 34:175-190.
- Morris, A.G. 1992. *The Skeletons of Contact: a study of protohistoric burials from the lower Orange River Valley, South Africa*. Johannesburg: Witwatersrand University Press.
- Ousley, S. & Jantz, R.L. 2012. Fordisc 3 and statistical methods for estimating sex and ancestry. In: *A Companion to Forensic Anthropology*. Ed.: D. Dirkmaat. UK: Wiley-Blackwell, pp.311-329.
- Pfeiffer, S. 2012. Conditions for evolution of small adult body size in southern Africa. *Current Anthropol*, 53(S6):383-394.
- Pfeiffer, S. & Sealy, J. 2006. Body size among Holocene Foragers of the Cape Ecozone, Southern Africa. *Am J Phys Anthropol*, 129:1-11.
- Phenice TW. 1969. A newly developed visual method of sexing the os pubis. *Am J Phys Anthropol* 30:297-302.
- Scott EC. 1979. Dental wear scoring technique. *Am J Phys Anthropol* 51:213-217.
- Steyn, M. & İşcan, M.Y. 1999. Osteometric variation in the humerus: Sexual dimorphism in South Africans. *Forensic Sci Int*, 106:77-85.
- Tobias, P.V. 1961. Physique of a desert folk: Genes, not habitat, shaped the Bushmen. *Natural History*, 170(2):16-24.
- Tobias, P.V. 1962. On the increasing stature of the Bushmen. *Anthropos*, 57:801-810.
- Truswell, A.S. & Hansen, J.D.L. 1976. Medical research among the !Kung. In: *Kalahari Hunter-Gatherers: Studies of the !Kung San and Their Neighbors*. Eds.: R.B. Lee & I. DeVore. Cambridge, Massachusetts and London: Harvard University Press, pp.166-194.

Table 1. Cranial and postcranial measurements.

	Champagne Castle 2009/023	Eland Cave 25/37	Mfongosi 25/36	Newcastle 2007/6
Cranial measurements				
Max cranial length	171			
Max cranial breadth	132			
Bizygomatic diameter	135			
Basion-bregma height	133			
Cranial base length	103			
Basion-prosthion length	102			
Maxillo-alveolar breadth	40			
Maxillo-alveolar length	50			
Upper facial height	66			
Min frontal breadth	92			
Upper facial breadth	110			
Nasal height	48			
Nasal breadth	31			
Orbital breadth	39			
Orbital height	35			
Biorbital breadth	103			
Interorbital breadth	28			
Frontal chord	102			
Parietal chord	112			
Occipital chord	95			
For magnum length	33			
For magnum breadth	28			
Mastoid length	27			27
Chin height	31		26	
Mandibular body height	27		24	
Mandibular body breadth	11		9	
Bigonal width	102			
Bicondylar breadth	118			
Min ramus breadth	34		30	
Max ramus breadth	40		38	
Max ramus height	55			
Mandibular length	76			
Mandibular angle	122°			
Postcranial measurements				
Clavicle: max length				
Clavicle: ant-post diameter				9
Clavicle: sup-inf diameter				7
Scapula: height				119*
Scapula: breadth				91
Humerus: max length	328*			
Humerus: epicondylar breadth	57*			
Humerus: vertical head diameter	41*			
Humerus: max diameter midshaft	19*		21	
Humerus: min diameter midshaft	17*		15	
Radius: max length	242*			
Radius: ant-post diameter	12*			
Radius: med-lat diameter	15*			
Ulna: max length	263*			
Ulna: ant-post diameter	12*			
Ulna: med-lat diameter	16*			
Ulna: physiological length	236*			
Ulna: min circumference	35*			
Sacrum: anterior length				

Sacrum: ant-sup breadth				
Sacrum: max trans base diameter				
Os coxa: height				170
Os coxa: iliac breadth				123
Os coxa: pubis length				81
Os coxa: ischium length				88
Femur: max length	418*			
Femur: bicondylar length	409*			
Femur: Epicondylar breadth	71*			
Femur: max diameter head	42*			
Femur: ant-post subtroch diameter	24*		25	
Femur: med-lat subtroch diameter	30*		34	
Femur: ant-post midshaft diameter	30*		30	
Femur: med-lat midshaft diameter	28*		31	
Femur: midshaft circumference	88*		91	
Tibia: length				
Tibia: max prox epiphyseal breadth				
Tibia: max dist epiphyseal breadth		38		
Tibia: max diameter nutrient for			33	
Tibia: med-lat diameter nutrient for			22	
Tibia: circumference nutrient for			85	
Fibula: max length				306
Fibula: max diameter midshaft				13
Calcaneus: max length				64
Calcaneus: middle breadth				37

*indicates that right side was used for measurement

Table 2. Dental measurements.

	Maxilla		Mandible	
	Champagne Castle	Newcastle	Champagne Castle	Newcastle
MD I1	6.3*			
BL I1	6.8*			
CH I1	9.9*			
MD I2	5.6	10.3		
BL I2	6.2	9.3		
CH I2	8.9	-		
MD C	7.8*		7.5	
BL C	8.5*		7.7	
CH C	5.4*		7.3	
MD PM1				
BL PM1				
CH PM1				
MD PM2				
BL PM2				
CH PM2				
MD M1		10.7*		
BL M1		10.7*		
CH M1		-		
MD M2			10.7	
BL M2			10.2	
CH M2			5.3	
MD M3			10.2	6.3*
BL M3			9.7	7.5*
CH M3			5.2	9.6*

*indicates that right side was used for measurement